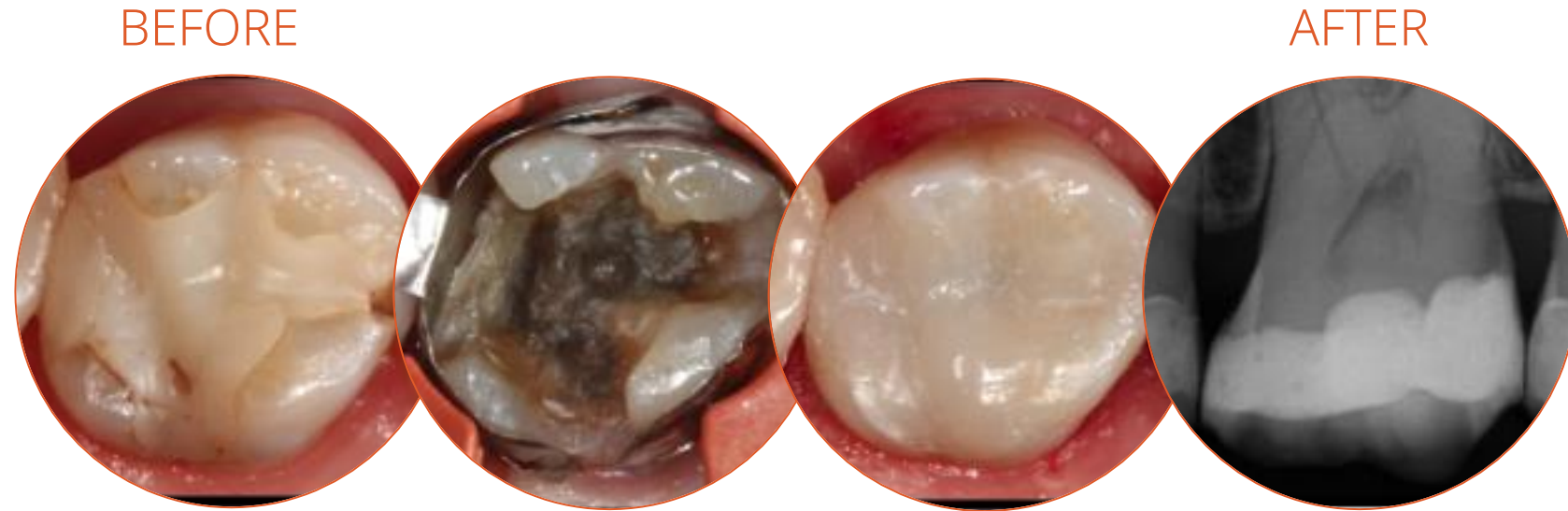


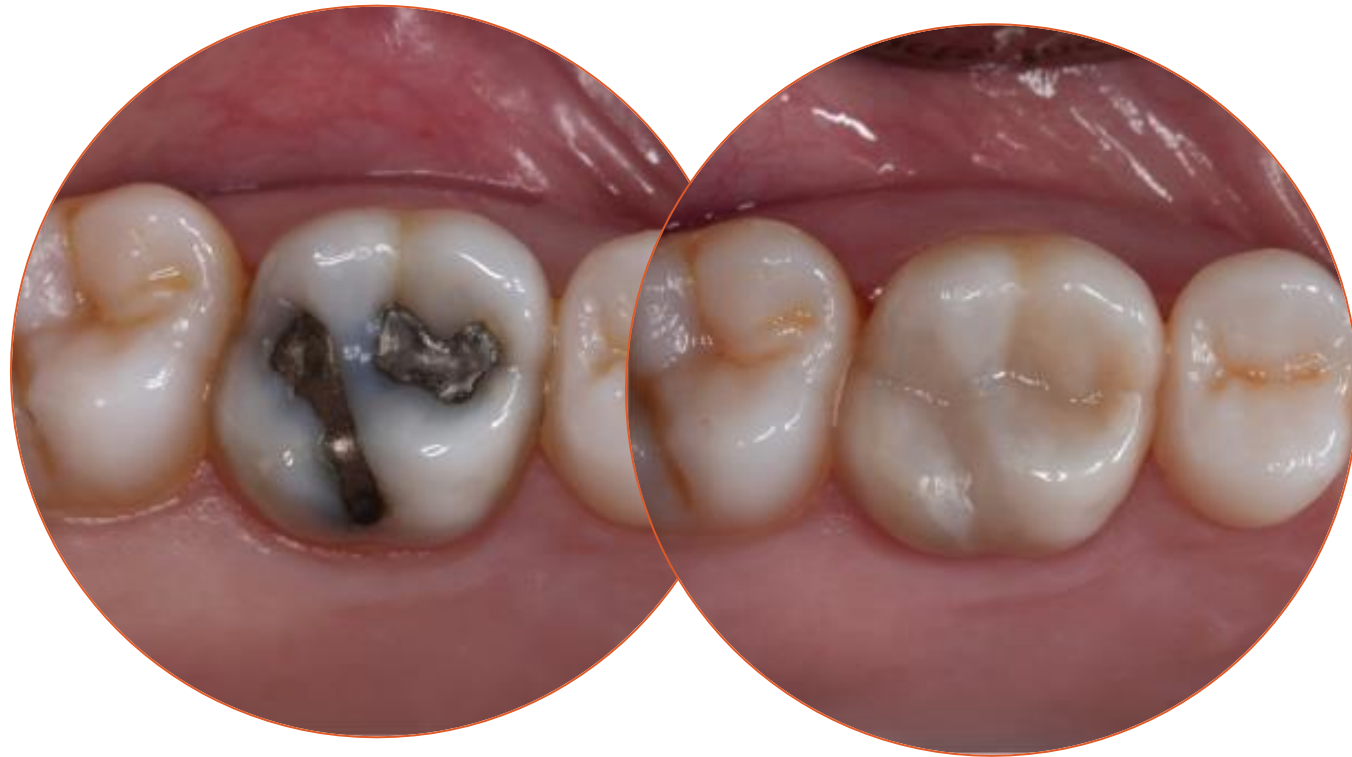Transcend Clinical Case



Patient presented with a failing composite restoration. Filling was removed, which revealed tattooing and mesial crack. The mesial crack was still a small, manageable size and therefore a direct bonded restoration could be done instead of an indirect crown restoration. Products used: Ultra-Etch™ etchant, Consepsis™ solution, and Peak™ Universal Bond adhesive. A very thin layer of A3 PermaFlo™ flowable composite was used for the initial layer. Transcend composite Universal Body shade was used to restore the tooth. Composite was adjusted according to occlusion and polished up beautifully.

Dr. Jaleena Fischer Jessop

Transcend Clinical Case



BEFORE

AFTER

Deep staining from amalgam tattooing presents one of the most difficult restoration situations to clinicians. In this case only the Transcend composite Universal Body shade was used to replace the amalgam, no blocker needed. Note the excellent color blending of the preserved oblique ridge.

Dr. Jaleena Fischer Jessop